

Clinical Report 1 (Acupuncture)

Post Herpetic Neuralgia

Masanori Takashi¹⁾ and Katsuhiko Arai²⁾

1) Tokai University Oiso Hospital,

2) Tokai University School of Medicine

Introduction

Herpes zoster is developed through the reactivation of the varicella zoster virus and subsequent recurrent infection, which is caused by the weakened immune system of the body due to aging, strain, overstress, and/or use of immune-suppressing drugs. The varicella zoster virus is infected latently at the dorsal root ganglion or the cerebral ganglia after contracting varicella. The virus causes inflammation in the ganglion cells and/or neural fiber, and then result in exanthema on the skin. Since herpes zoster has higher incidence with aging, one out of 5-10 cases is supposedly develop the disease in the Japanese aging society of recent years. Generally, a rash appears at primary neural regions on one side. The rash can be cured by providing antiviral medication for 2-4 weeks, however the rash part may leave lingering pains. This pain is called herpes zoster pain. NSAIDs are effective to relieve the pain. However, approximately 10-15 percent of the cases of herpes zoster and herpes zoster pain can transition to post herpetic neuralgia (PHN)¹⁾. Many researchers have reported acupuncture is effective to this pain. We have treated many cases of this kind. One case is introduced here:

[Case] 77 years old, Female, Retired

[Chief complaint] Pain in the right-side back and the right-side of abdomen

[Present Illness]

In late June this year, the patient received urgent treatment for a back pain. On the previous day, the patient felt a pain in the right-side of her back after gardening. A bladder was observed in part, so treatment by dermatologist was suggested. The dermatologist diagnosed the patient with herpes zoster,

and antiviral medication was provided. Bladders disappeared two months later. However, burning and tingling ache still remains. Pain occurs when clothes rub against the affected area. The patient was diagnosed as PHN by a dermatologist. Painkiller was administered but the pain still remained. The patient wished for acupuncture treatment, and a dermatologist referred her to my acupuncture clinic.

Other symptoms include light sleep, constipation, heat, and fatigability.

[Past history]

Lumbar disc herniation (age of 50), Operation for gastric neoplasm (age of 43), Bronchial asthma (age of 55), Osteoporosis (age of 70). The patient sought medical advice for lumbago at an acupuncture clinic five years ago, and was diagnosed with kidney yin vacuity. The patient was cured after treatment. Thereafter, the patient continued therapy once a month for health maintenance.

[Present status]

Height 155cm, Weight 40kg. Pulse is deep, string-like, rapid pulse. Dark red tongue, cracked with a whitish coating. The pain VAS is 80mm. The patient has "slow smarting pain from the inside" and "superficial pain on the skin". Cutaneous discoloration is observed from the left-side back to the side abdomen. Allodynia was observed in the side abdomen. Heat in the lower legs was felt. Constipation was observed.

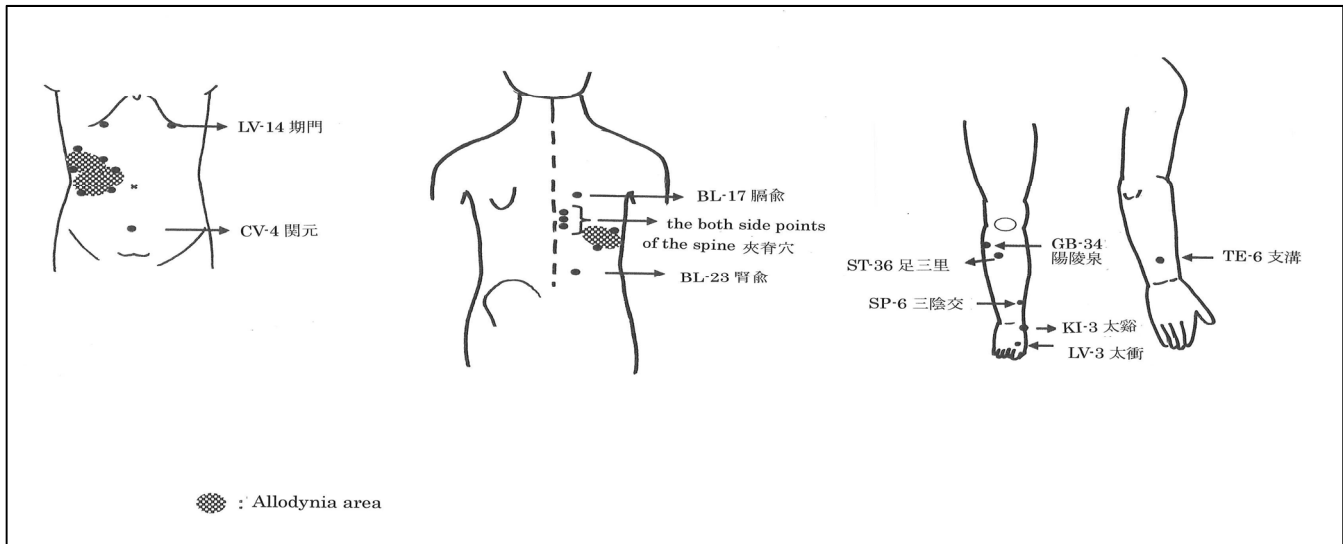
[TCM diagnosis]

Blood stasis, Deficiency of both Qi and yin of Kidney

[Therapeutic principle]

Active blood and resolve stasis, Nourish yin and tonify the kidney

[Acupoint selection] TE-6, GB-34, LV-14, LV-3, Ouch point (around the discolored part), SP-6, BL-17, Low-frequency waves (Low frequency 3Hz and High frequency 30Hz, for 10 minutes) are irradiated at the both side points of the spine from Left TH10-12., BL-23



[Explanation]

Pain is produced at lesser yang tripple energizer channel and reverting yin liver channel in the legs. Therefore, "clearing the liver, regulating Qi and unblocking the meridian" was done combining LV-14, LV-3, and GB-34¹⁾. Then purgation with twirling was practiced at the Triple Energizer Meridian (TH6) along the rib to heal the pain.²⁾ Unblock the meridian by needle pricks surrounding the discolored part of the skin. Furthermore, promote blood flow and free the network vessels by purgation with twirling on SP-6 and BL-17 to strengthen "active blood and resolve stasis". The both side points of the spine were treated in the nerve field where rash developed. I thought that this would stimulate the nerve field which is defined in Western medicine.

Needles Used: Seirin-made sterilized acupuncture needle, length 1cun6fen, No. 1

[Course] Treatments are planned twice a week.

Second session: Pain was relieved immediately after treatment, but it reoccurred in the evening of the same day.

Third, fourth and fifth session: No obvious changes were observed.

Sixth session: The pain VAS was 70mm. The slow smarting pain from the inside was gradually relieved. The area of allodynia had become 2/3.

Seventh session: The pain VAS became 60mm. The number of treatment was reduced to once a week.

Eighth session: No changes were observed. "Active blood and resolve stasis" was strengthened by practicing pricking bloodletting therapy at the point of tenderness. The patient had got a sense of relief.

Tenth session: The sense of relief continues. The pain VAS has become 30mm. The area of allodynia had become 1/3.

Twelfth session: The pain VAS became 15mm. The area of allodynia further dwindled.

Thirteenth session: Pain and allodynia almost disappeared. ST-36, KI-3, and CV-4 were added to tonify the kidney.

Fourteenth session: The pain VAS has become 0mm. The color of skin was improved. Allodynia disappeared. So treatment ended. Monthly treatment is being provided for health maintenance.

[Discussion]

Herpes zoster has been recognized from ancient times. Several different aliases exist. The representative name is "Fire Band Rash (火帶瘡)". In a book written in 1602, titled "Standards of Patterns and Treatments" (part of surgery), it says "The liver fire is overwhelming. It flows into the bladder, and it is clad with the belt vessel. Therefore it looks like bundled bands." This might have implied herpes zoster. Even in this case, a rash was observed in the

liver meridian and the belt vessel at the beginning. The case was considered to be suffering from the same disease mentioned in the old book.

A book titled "The Diagnosis and Therapy of TCM with Symptoms (Part 2)" mentioned that herpes zoster has the excess pattern of "the heat exuberance and dampness stagnation" and "the heat toxin burns the natural aspect", along with the deficiency pattern of "the spleen deficiency with dampness" and "the Qi deficiency and blood stasis." Now that two months have passed since herpes zoster developed in this case, and the acute period had passed, it is supposed that deficiency of both Qi and yin of Kidney occurred in the body and the state of blood stasis appeared. So high-frequency stimuli including the practice of "activate blood and resolve stasis" were given at the local route; thus, the symptoms were successfully relieved.

Additionally, the number of patients referred by dermatologists has increased after this case. I believe that acupuncture treatment has a considerable role within the general medicine.

Reference

- 1) LI Shi-zhen: Clinical Elaboration of the Common Shu Points, p.749-758, People's Medical Publishing House Co., LTD, 1985 (in Chinese)
- 2) Textbook of practical acupuncture, p125, Tianjin Science and Technology Press, 1995 (in Chinese)
- 3) LI Shi-zhen: Clinical Elaboration of the Common Shu Points, p.420-430, People's Medical Publishing House Co., LTD, 1985 (in Chinese)
- 4) Textbook of the Acupuncture Prescriptions, p87-88, China Press of Traditional Chinese Medicine, 2005 (in Chinese)
- 5) The Diagnosis and Therapy of TCM with Symptoms (Part2), p.421-422, Ryogenshoten, 1998 (in Japanese)
- 6) Sugawara, Masaaki, Yoshikawa, Keiji: Effect of Electric Acupuncture Therapy for Post Herpetic Neuralgia, The Japanese journal of acupuncture & manual therapies, 65: 39-46, 2006 (in Japanese)

* This case study is based on the report published in the Vo. 56 No.1 2009 issue of "The Journal of Kampo Medicine" (Japanese version), and then the contents have been slightly modified and translated into English.